

► <http://dx.doi.org/10.19048/2411-8729-2019-5-4-32-33>

## РЕДКИЙ СЛУЧАЙ ТРАВМЫ ШЕИ ПРИ ИЗВЛЕЧЕНИИ ТЕЛА ИЗ ВОДЫ

Виндгассен М., Ресслер Л., Тсокос М., Эстерхельвег Л.

**Аннотация.** Посмертные повреждения могут ошибочно расцениваться как прижизненные при наружном или внутреннем исследовании трупа. Если обстоятельства наступления смерти известны заранее, дифференциальная диагностика прижизненных и посмертных повреждений обычно не вызывает сложностей у опытного судебно-медицинского эксперта. Однако в некоторых случаях, когда информации недостаточно или она отсутствует, интерпретация обнаруженных на вскрытии изменений может являться камнем преткновения. Предлагаем вашему вниманию случай необычного посмертного повреждения шеи при извлечении трупа из воды, механизм которого удалось установить лишь на основании тщательной реконструкции всех обстоятельств дела.

**Ключевые слова:** повреждение шеи, утопление

## STRANGULATION BY RECOVERY – A RARE MANIFESTATION OF A RECOVERY INJURY

M. Windgassen\*, L. Rößler, M. Tsokos, L. Oesterhelweg

Institute for Legal Medicine and Forensic Sciences, Charité-Universitätsmedizin Berlin

**Abstract.** Recovery injuries can be misinterpreted as vital injuries during the external examination or the autopsy of a body. While usually – if the finding situation and the circumstances of recovery are known – there should be no problem for the experienced forensic pathologist to differentiate between vital injuries and recovery injuries, in some cases with missing information there might be pitfalls in the interpretation of the findings. We report a case of an unusual recovery injury which could be solved through careful reconstruction of the circumstances.

**Keywords:** strangulation, unusual recovery injury

**MARC Windgassen** – Dr. med. M. Windgassen, Institut für Rechtsmedizin Charité-Universitätsmedizin • Berlin Turmstr. 21 Geb. N – 10559 Berlin • (030) 450 525 045 • {ORCID:0000-0001-6999-8524}

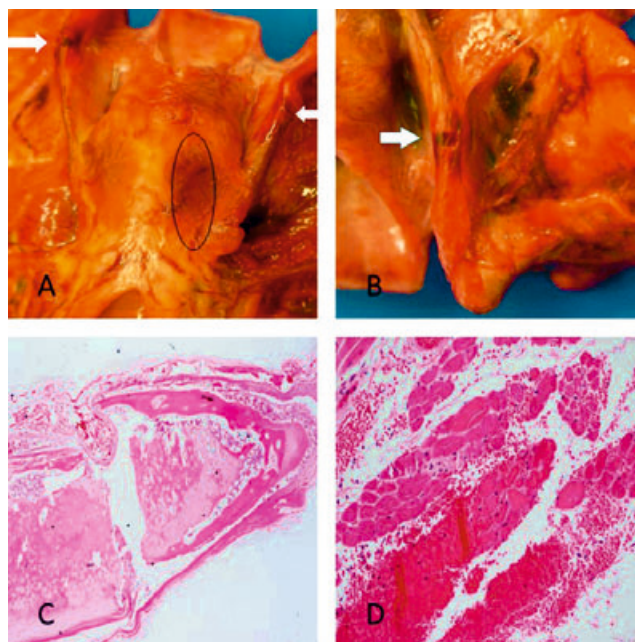
### ◇ CASE REPORT

On 17.11.2017, a stroller saw the lifeless body of a 62-year old woman floating in the Teltow channel in Berlin. Police officers and paramedics recovered the body from the water and an emergency physician tried to resuscitate her for about 60 minutes without success. While the resuscitation attempts were still ongoing, the companion of the woman showed up at the scene and reported that she was suffering from depression. The external examination of the police revealed no specific features. The bag of the deceased was found at the bankside. A forensic pathologist was not called to the scene. The police suspected a suicide and an autopsy was performed on order of the state prosecutor several days after the incident.

### ◇ AUTOPSY FINDINGS

The autopsy was performed in the Institute for Legal Medicine and Forensic Sciences, Charité-Universitätsmedizin Berlin on 27.11.2017. External examination of the body revealed punctuation marks at the neck and the right lower arm, a small abrasion above the right eye and one single petechial bleeding in the upper lid of the left eye. No signs of a longer immersion of the body could be seen.

Via autopsy and post-mortem computertomography signs of drowning could be detected: bleedings beneath the surfaces of the lungs and the heart, frothy secretion down to the smaller airways, water in the sphenoid sinus (Sign of Svechnikov), three stages of the gastric content (Wydler's sign). The lungs showed edema and emphysema and 300 ml effusion was found in each side of the chest cavity. Due to the resuscitation attempts, we found soft tissue bleedings in



**Fig. 1. A:** Larynx with fractures of the upper laryngeal horns (arrows) and bleedings in the *M. posticus* (outlined). **B:** Detail of the fracture of the left laryngeal upper horn. **C:** Fracture of the right laryngeal horn with no signs of bleeding (HE-staining). **D:** Bleeding into the para-laryngeal muscle-tissue without signs of cellular reaction (HE-staining)

accordance with the punctuation marks and fractures of the ribs 3–6 on the right side and 5 on the left side. Suspicious findings were detected at the larynx: Both upper laryngeal cornea were broken (Fig. 1A, 1B, 2A) with surrounding bleedings in the soft tissues. On the right side there was also a bleeding in the *M. posticus* (Fig. 1A). Additionally bleedings

• Received: 23.09.2019 • Accepted: 31.12.2019

**For reference:** Windgassen M., Rößler L., Tsokos M., Oesterhelweg L. Strangulation by recovery – a rare manifestation of a recovery injury. *Russian Journal of Forensic Medicine*. 2019;5(4):32-33. (In Russ.) <http://dx.doi.org/10.19048/2411-8729-2019-5-4-32-33>.



**Fig. 2. A: Laryngeal fractures in the postmortem CT-imaging (outlined). B: Reconstruction of the recovery. C: Reconstruction of the recovery with powerful pulling at the collar. D: Excerpt from the surveillance camera recording [outlining by the police]. In the video can be seen that the woman jumps into the water and no other persons are at the scene.**

in the soft tissues next to the articulation between the cricoid and the thyroid cartilage were detected.

#### ◇ TOXICOLOGICAL ANALYSIS

Paracetamol, Pantoprazol and Bisoprolol were found in therapeutic concentrations. Bromazepam was found in more-than-therapeutic concentrations in the venous blood and the gastric content. The ability to act was (according to a specialist's expertise) not abolished.

#### ◇ HISTOPATHOLOGICAL EXAMINATIONS

Heart, liver, kidneys and brain showed no significant pathological findings. The lungs presented a severe emphysema with rupture of alveolar membranes and a decent edema. The fracture of the right upper laryngeal corn showed no bleedings within the cartilage (Fig. 1C). The muscle bleeding was fresh, with no signs of organization (Fig. 1D).

#### ◇ RECONSTRUCTION OF THE RECOVERY

Due to the findings at the larynx, for which no sufficient explanation could be found, we informed the homicide squad and the state prosecutor about the suspicion of a homicide via strangulation. Despite the fact that the companion gave inconsistent statements to the police, no further evidence could be found. On 04.12.2017, a reconstruction of the recovery by using a clothed dummy was performed by the police officers and paramedics who were originally involved. They demonstrated that the body, face down, was grabbed at the coat and its collar to pull it up the bankside (Fig. 2B, 2C). Later the police could secure the video of a surveillance camera from

an industrial facility on the opposite riverside. The video left no doubt that the woman did jump into the water without any involvement of another person (Fig. 2D).

#### ◇ DISCUSSION

If bodies are recovered from the water floating injuries, injuries from ship's propellers as well as recovery injuries can aggravate the interpretation of the findings [5]. Even strangulation marks in cases of recovery of bodies via rope have been reported [6]. In the case reported here, the autopsy findings suggested a strangulation. Signs of strangulation in combination with the signs of drowning could reflect a scenario of strangling to unconsciousness followed by a drop of the body into the water. The bleedings in soft tissues, which we found during the autopsy, can be interpreted as a sign of vitality, but the problem of agonal or early-postmortem soft tissue bleedings and the differentiation to vital injuries is well known [2,3]. Since we found no external signs of a neck compression, a compression via headlock e.g. was also taken into consideration. Since no signs of congestion of the head could be found, the evidence contradicted this theory. The emergency physician reported that the intubation was uncomplicated thus ruling out an intubation injury, especially considering that a symmetric fracture of both upper laryngeal cornea would be a very uncommon intubation-injury [1]. Floating injuries were also not a sufficient explanation given the nature of the injuries and the missing of any abrasion or other external mark. It is known that recovery via ropes can lead to strangulation-findings [4,5], but in the given case it was clear that no ropes were used to recover the body. It was the thorough reconstruction of the recovery of the body that provided a sufficient explanation for the strangulation findings. The grabbing and pulling of the collar of the sodden coat can lead to the laryngeal fractures and in early postmortem stage to the tissue bleedings.

#### ◇ CONCLUSION

The exact knowledge of the finding situation and the circumstances of recovery can be crucial for the secure interpretation of autopsy findings. A reconstruction of the recovery may help to explain suspicious findings. But, of course, it cannot be emphasized enough that suspicious findings must never be downplayed if there is no sufficient explanation.

#### ◇ LITERATURE

1. Buschmann C, Tsokos M Frequent and rare complications of resuscitation attempts. *Intensive care Med.* 2009;35: 397-404
2. Fieguth A, Albrecht UV, Bertolini J, Kleemann WJ. Intra-cartilaginous haemorrhagic lesions in strangulation? *Int J legal Med.* 2003;17:10-13
3. Madea B, Grellner W. Vitale Reaktionen. *Rechtsmedizin.* 2002;12:378-394
4. Maxeiner H. Zum Beweiswert von Kehlkopfverletzungen. *Arch Kriminol.* 1983;171:33-44
5. Vennemann B, Brinkmann B (2003) Der Tod im Wasser. *Rechtsmedizin.* 2003;13:201-215
6. Zollinger U, Pollak S. Vortäuschung von Strangulationsbefunden durch postmortale Bergungs- und Transportmaßnahmen. *Beitr Gerichtl. Med* 1989;47: 479-486

Об авторях • Authors

**MARC Windgassen** – Dr. med. M. Windgassen, Institut für Rechtsmedizin Charité-Universitätsmedizin Berlin Turmstr. 21, Geb. N – 10559 Berlin, (030) 450 525 045

► **Declaration of financial and other relationships:** The study had no sponsorship. Authors are solely responsible for submitting the final manuscript to print. All authors participated in the development of the concept of the article and the writing of the manuscript. The final version of the manuscript was approved by all authors. The authors are grateful to anonymous reviewers for helpful comments. The authors declare no apparent or potential conflicts of interest related to the publication of this article.