

► <http://dx.doi.org/10.19048/2411-8729-2019-5-3-39-41>

СУИЦИДАЛЬНОЕ ОТРАВЛЕНИЕ ЧИСТЯЩИМ СРЕДСТВОМ ДЛЯ УНИТАЗОВ

К. Бушманн*, С. Хартвиг, М. Тсокок

Институт судебной медицины и криминалистики, Шарите – Медицинский университет, Берлинский университет им. Гумбольдта и Свободный университет Берлина, Берлин, Германия

Аннотация. В статье рассматривается случай смерти 44-летней женщины, страдавшей параноидной шизофренией и совершившей самоубийство путем приема внутрь примерно 4 литров средства для чистки унитазов. При исследовании трупа установлены признаки быстрого наступления смерти, а также обширные дефекты слизистой оболочки пищевода и желудка, сопровождавшиеся смертельным кровотечением. Результаты аутопсии и токсикологического исследования рассмотрены в свете имеющихся публикаций.

Ключевые слова: самоубийство, отравление, бытовая химия

SUICIDAL INTOXICATION WITH TOILET BOWL CLEANER

C. Buschmann*, S. Hartwig, M. Tsokos

Institute of Legal and Social Medicine, Charité – Medical University, Humboldt University of Berlin & Free University of Berlin, Berlin, Germany

Abstract. We describe and discuss the case of a 44-year old paranoid woman who committed suicide by ingestion of approximately 4 litres of toilet bowl cleaner. Autopsy findings consisted of central dysregulation and extensive mucosa ulcerations of oesophagus and stomach with fatal bleeding. Autopsy and toxicological results are presented in the light of the literature.

Keywords: suicidal intoxication, suicide, household chemicals

BUSCHMANN Claas Thade – MD, Dr. Sci. (Med.), main place of work: Institute of Legal Medicine and Forensic Sciences, Charité – Medical University, Humboldt University of Berlin & Free University of Berlin • **Chariteplatz 1, 10117 Berlin, Germany** • claas.buschmann@charite.de

◇ CASE

A 44-year-old woman was found lifeless on a bed in a mental home for the mentally ill. She was last seen alive by a neighbour 5 days earlier. She was found because an employee of the residence had opened the apartment after the woman had not taken an appointment. Next to the body were four nearly emptied 1-liter-bottles of the CLINÄR® toilet bowl cleaner. Furthermore, four but still sealed 1-liter bottles were also found in the room. A farewell letter did not exist.

The woman had smothered her roommate in a psychiatric ward 11 years earlier with a pillow due to a paranoid psychosis, and was subsequently held psychiatric for 5 years. For a long time she lived now in the supervised dorm. Suicide intentions were unknown to the attending physicians and caregivers. However, she had developed an obsessive-compulsive disorder with regard to cleaning / washing, and therefore hoarded various detergents and cleaning agents.

◇ AUTOPSY FINDINGS

As cause of death, the autopsy revealed a central regulatory failure (brain and pulmonary oedema, blood congestion of the internal organs and dilation of the hollow organs). In addition, extensive ulcerations of the oesophageal and gastric mucosa (Fig. 1–3) were found, with bleeding into the gastrointestinal tract and vomiting of blood (Fig. 4). The stomach content, a total of 1.200 ml, was permeated with haematin and had a pungent smell. Apart from a slight general arteriosclerosis, no further pathological organ changes of a significant kind or evidence of external trauma was present.

◇ HISTOLOGY

After histological examination, the mucosa of the upper gastrointestinal tract was autolytic, but in some areas markedly degenerative-necrotic (Fig. 5–6). The submucosal structures showed a histologically indeterminate accumulation of foreign substances (deposits of toilet bowl cleaner), especially in the stomach wall. Due to the toxically induced damage, the squamous epithelial layers of the upper gastrointestinal tract are detached in the sense of a desquamation.

◇ TOXICOLOGY

Toxicological analysis of blood and tissue samples of the deceased revealed no evidence of the presence of toxic substances at the time of death; an alcoholic influence could not be detected. The preserved gastric contents were as stinging smelling, slightly acidic (pH 5–6), with food components and bloody liquid.

◇ TOILET CLEANER CLINÄR®

The toilet bowl cleaner CLINÄR® (Fig. 7) manufactured by Luhns GmbH / Wuppertal, Germany, is distributed in Germany by the food discounter ALDI. It is a formulation based on 4 % ant- and 2 % citric acid-based, which as further ingredients 0.7 % aluminum sulfate, 0.1 % alkoxyated fatty alcohol C18–8, 0.1 % cocamidopropyl betaines, xanthan gum, perfume and contains dyes. The pH is 2; the product is labeled as “irritant”.

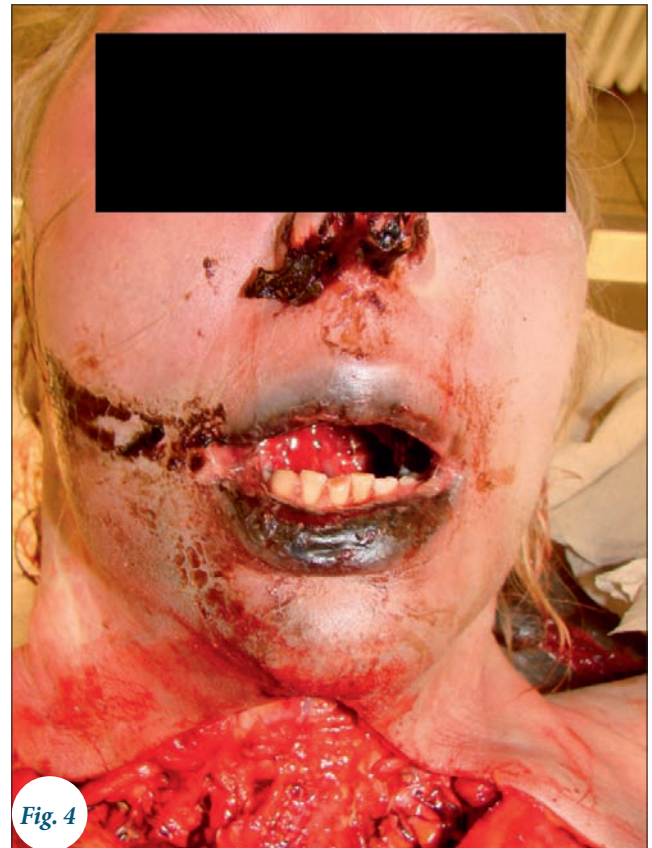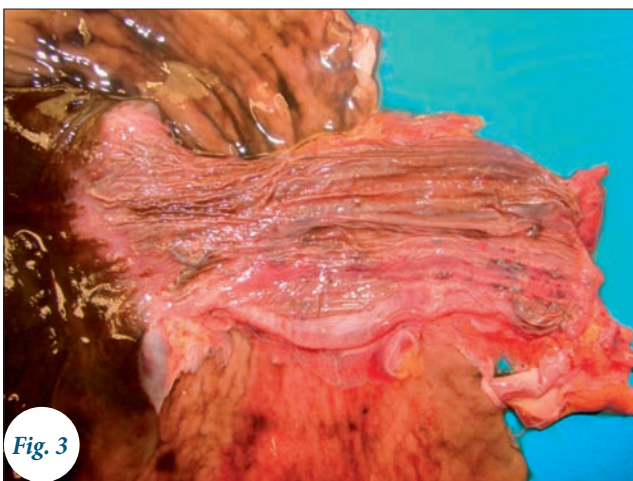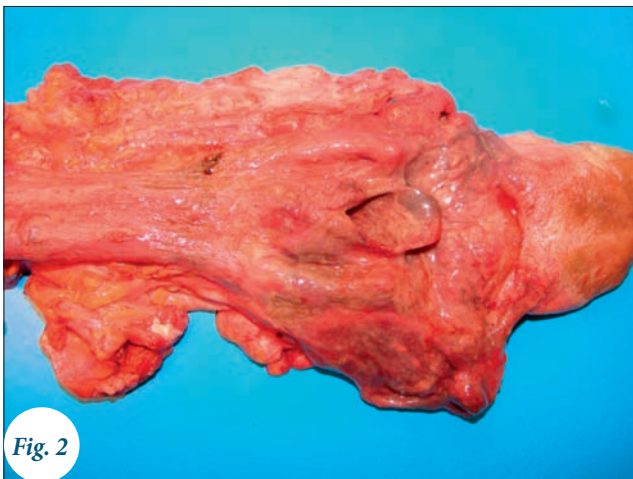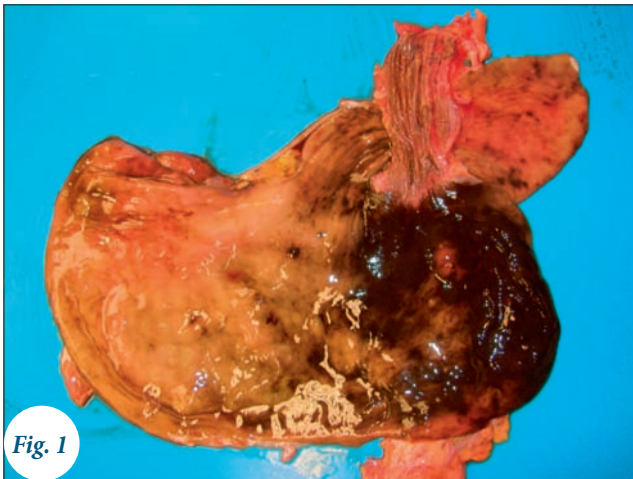◇ DISCUSSION

Suicide-related cases of poisoning by household cleaners are relatively rare in forensic practice, only individual case reports exist [3]. Although a recent study reported on a suicidal

• Received: 18.07.2019 • Accepted: 16.09.2019

Для цитирования: Бушманн С., Хартвиг С., Тсокок М. Суицидальное отравление чистящим средством для унитазов. *Судебная медицина*. 2019;5(3):39-41. <http://dx.doi.org/10.19048/2411-8729-2019-5-3-39-41>.

For reference: Buschmann C., Hartwig S., Tsokos M. Suicidal intoxication with toilet bowl cleaner. *Russian Journal of Forensic Medicine*. 2019;5(3):39-41. (In Russ.) <http://dx.doi.org/10.19048/2411-8729-2019-5-3-39-41>.



*Fig. 1-4. Extensive destruction of the gastric and esophageal mucosa with hematemesis after lethal toilet-cleaner intoxication
Рис. 1-4. Обширные дефекты слизистой оболочки желудка и пищевода с признаками рвоты кровью после смертельного отравления средством для чистки унитаза*



*Fig. 7. Toilet bowl cleaner CLINÄR®
Рис. 7. Средство для чистки унитаза CLINÄR®*

background in one third of the cases of corrodible injections [1], only 27 lethal outcomes (n = 206,636) were reported after detergent ingestion in another study [5].

In the context of (accidental) intoxication by (in part insufficiently secured) household cleaners, especially children are affected; lethal poisoning is the fifth leading cause of death in childhood worldwide, with 35,000 cases annually [4]. As a pathomechanism leading to death, fulminant blood loss from

mucosal lesions is followed by metabolic acidosis. If this can be mastered, the event is survived. However, in 4.4% of the survived cases, mucosal strictures remain and must be treated surgically [2]. Furthermore, the risk of esophageal carcinoma is increased 30 to 40 years after ingestion.

In the present case, it can be assumed that the event might have been possibly have survived, if the suicide intentions of the patient would have been known. Accordingly, if there had

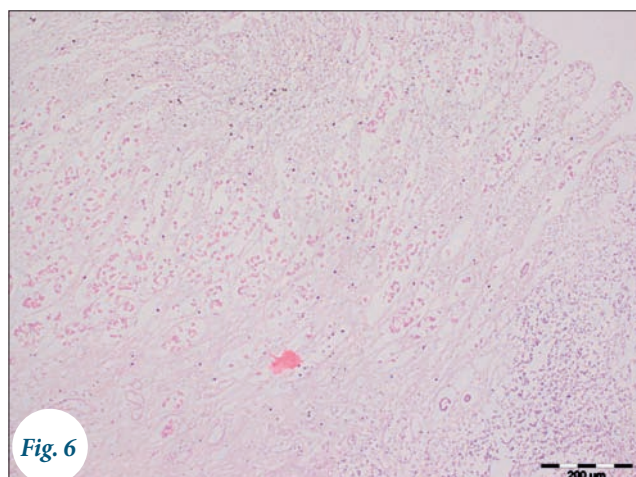
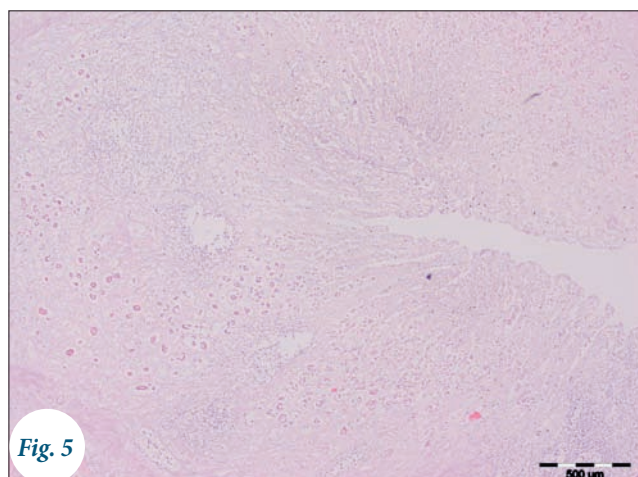


Fig. 5, 6. Necrotic gastric mucosa
Рис. 5, 6. Некроз слизистой оболочки желудка

been a closer mental health care, the patient would have been found earlier after ingestion.

Noteworthy is also the absence of any consciousness-altering substances at the time of death. Thus, in the present case, a slow and presumably painful death is to be assumed. The pH increase in the stomach contents can be explained in addition to the anionic surfactants contained with the blood and food enforcement of the cleaning liquid. The public prosecutor quit the death investigation.

◆ REFERENCES

1. Arévalo-Silva C., Eliashar R., Wohlgelernter J., Elidan J., Gross M. Ingestion of caustic substances: a 15-year experience. *Laryngoscope*. 2006;116:1422-1426.
2. Garcna D. E., Castro F. M., Romero G. M., Castilla H. L. Upper gastrointestinal tract injury caused by ingestion of caustic substances. *Gastroenterol Hepatol*. 2001;24:191-195.
3. Kobayashi K., Fukushima H. Suicidal poisoning due to hydrogen sulfide produced by mixing a liquid bath essence containing sulfur and a toilet bowl cleaner containing hydrochloric acid. *Chudoku Kenkyu*. 2008;21:183-188.
4. Patel B., Devalia B., Kendrick D., Groom L. Validating parents' self-reports of children's exposure to potentially toxic substances within the home. *Inj Prev*. 2008;14:170-175.
5. Ramasamy K., Gumaste V. V. Corrosive ingestion in adults. *J Clin Gastroenterol*. 2003;37:119-124.

Об авторах • Authors

BUSCHMANN Claas Thade – PhD, Dr. Sci. (Med.), Institute of Legal Medicine and Forensic Sciences, Charité – Medical University, Humboldt University of Berlin & Free University of Berlin • **Chariteplatz 1, 10117 Berlin, Germany** • claas.buschmann@charite.de

TSOKOS Michael – PhD, Dr. Sci. (Med.), Institute of Legal Medicine and Forensic Sciences, Charité – Medical University, Humboldt University of Berlin & Free University of Berlin • **Chariteplatz 1, 10117 Berlin, Germany** • michael.tsokos@germed.berlin.de

HARTWIG Sven – PhD, Dr. Sci. (Med.), Institute of Legal Medicine and Forensic Sciences, Charité – Medical University, Humboldt University of Berlin & Free University of Berlin • **Chariteplatz 1, 10117 Berlin, Germany** • sven.hartwig@charite.de

► **Декларация о финансовых и других взаимоотношениях:** Исследование не имело спонсорской поддержки. Авторы несут полную ответственность за предоставление окончательной версии рукописи в печать. Все авторы принимали участие в разработке концепции статьи и написании рукописи. Окончательная версия рукописи была одобрена всеми авторами. Авторы благодарны анонимным рецензентам за полезные замечания. Конфликт интересов отсутствует.

► **Declaration of financial and other relationships:** The study had no sponsorship. Authors are solely responsible for submitting the final manuscript to print. All authors participated in the development of the concept of the article and the writing of the manuscript. The final version of the manuscript was approved by all authors. The authors are grateful to anonymous reviewers for helpful comments. The authors declare no apparent or potential conflicts of interest related to the publication of this article.